

# Hypertrophic Obstructive Cardiomyopathy

## Definition

Inherited genetic condition in which the heart muscle becomes abnormally thick and prone to tachy-arrhythmias.

## History/Physical Exam

Often presents in young, athletic patients.

May present with dyspnea, syncope/presyncope, angina, palpitations, orthopnea, paroxysmal nocturnal dyspnea (PND), CHF, and sudden cardiac death. Additionally, systolic crescendo-decrescendo murmur, decreasing on standing.

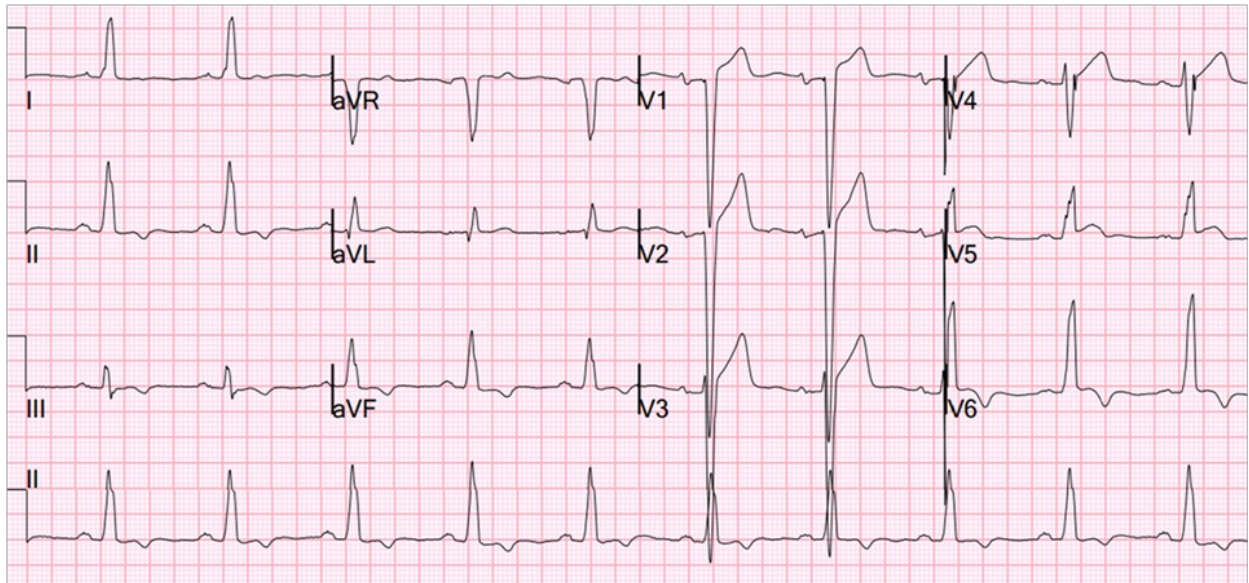
## Key 12-Lead Features

High Left Ventricular Volume, possibly w/ pathological Q-waves in lateral/anterior leads, ST changes and/or T wave inversions.

## Key Treatment Points

Patient advocacy for a cardiology consult

## 12 Lead ECG Samples



[Further Reading](#)

## References

Helmy, S. M., Maaouf, G. F., Shaaban, A. A., ElMaghraby, A. M., Anilkumar, S., Shawky, A. H. H., & Hajar, R. (2011). Hypertrophic Cardiomyopathy: Prevalence, Hypertrophy Patterns, and Their Clinical and ECG Findings in a Hospital at Qatar. *Heart Views : The Official Journal of the Gulf Heart Association*, 12(4), 143-149. <http://doi.org/10.4103/1995-705X.90900>.

